

Giant Pleomorphic Adenoma of the Parotid

Paul E. Lomeo, DO^a

Muskegon, Michigan

The photographs are preoperative (Figures 1 and 2) and postoperative (Figures 3 and 4) views of a seventy-four-year-old white woman who has a very large left parotid mass of thirty-five years duration. It started out at about 1 centimeter at the angle of the mandible, and continued to increase in size. At first she did not want anything done, but as a seventy-four-year-old with grandchildren, she wanted the mass removed. She was taken to surgery and a facial nerve monitor was applied. Left parotidectomy

was done. There was no postoperative facial palsy (Figures 3 and 4). This was a benign pleomorphic tumor which is the most common tumor of the parotid gland. These make up approximately 80% of all parotid masses. The second most common is a Warthin's tumor. The most common malignant tumor of the parotid is mucoepidermoid. These photographs show that even a benign pleomorphic adenoma can continue to grow and cause multiple problems.




Figure 1. Preop — frontal view.

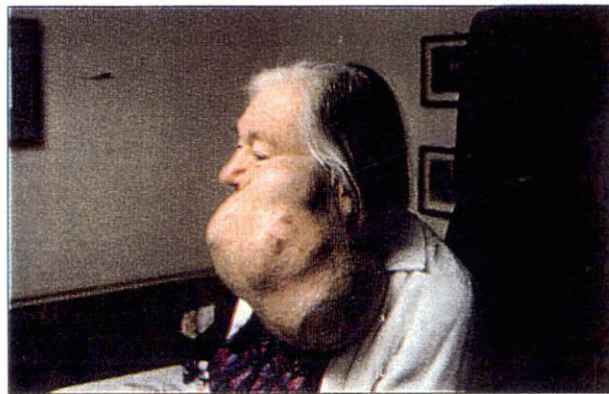

Figure 2. Preop — side view.



Figure 3. Postop — frontal view.

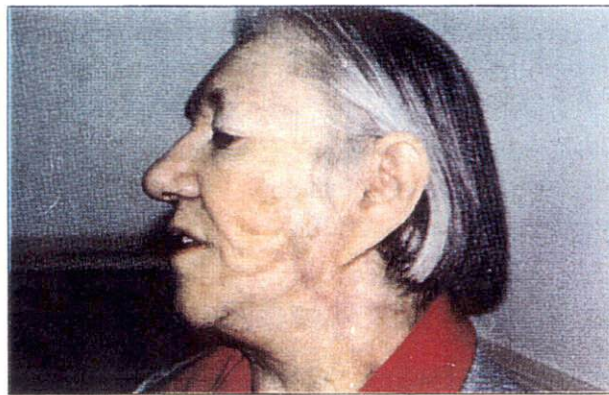

Figure 4. Postop — side view.

^aShoreline ENT, PC, 1762 Wagner Avenue, Muskegon, MI 49442; Phone: 616/777-2625; Fax: 616/773-8560.